

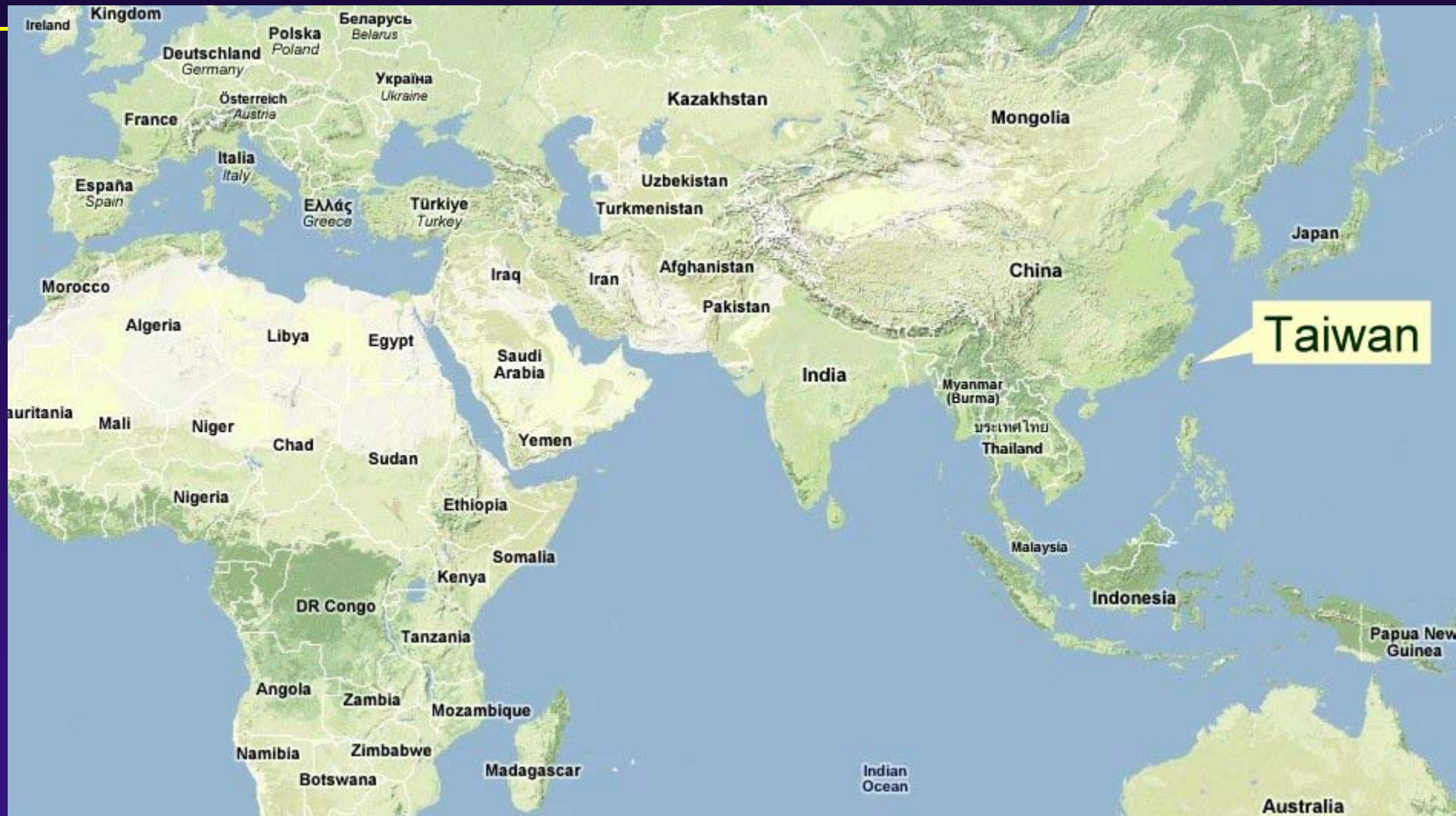Angiostrongylus cantonensis **in Taiwan**

Hung-Chin Tsai, M.D

Aug 17-18, 2011

***Section of Infectious Diseases, Department of
Medicine, Kaohsiung Veterans General
Hospital, Kaohsiung, Taiwan and National
Yang-Ming University, Taipei, Taiwan***





Outline

- Case presentation of eosinophilic meningitis caused by *A. cantonensis* infection.
- Description of three outbreaks, clinical studies and epidemiological changes
- Intermediate host in Taiwan
- Control and prevention of *Pomacea canaliculata* in rice farm and water bamboo farm

Case presentation

- Chart number: 5454988
- 28 y/o, male, single
- Chief complaint: fever, headache and diplopia for days
- Past history: eating snails one month ago

Case presentation

- Lumbar puncture: WBC 230/cumm, RBC 210/cumm, L/N/M 67/31/2, Protein 133mg/dl, glucose 51mg/dl(serum 114mg/dl).
- Peripheral blood: WBC 11170/cumm, HgB 15.5 g/dl, S/L/M/E 53/22/4/21, Plt 264k
- Neurology exam:left abducens nerve palsy
- CSF data (2nd day): WBC 20, RBC 460, N/L/E 7/23/70

Immunodiagnosis of human eosinophilic meningitis using an antigen of *Angiostrongylus cantonensis* L₅ with molecular weight 204 kD

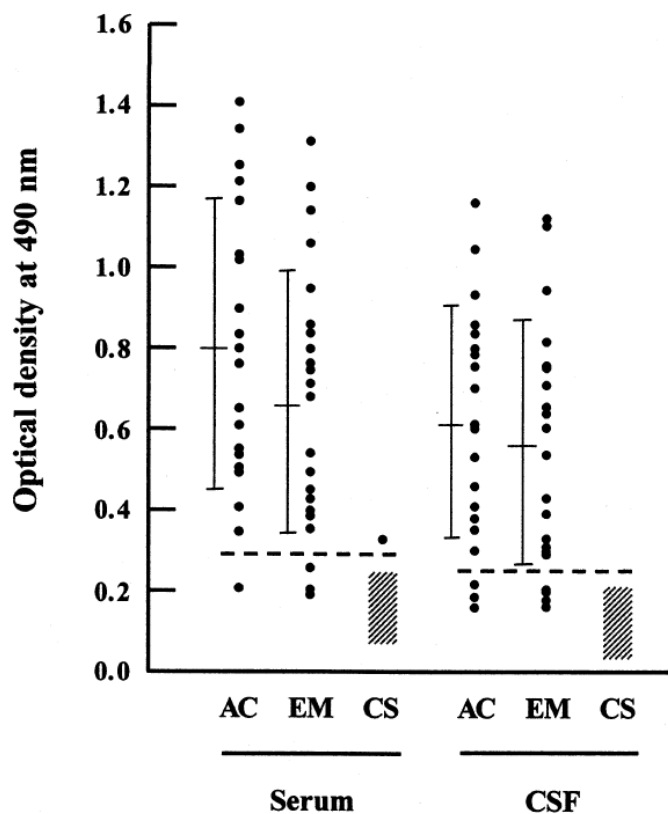
Soi-Moi Chye ^a, Jui-Hsien Chang ^b, Chuan-Min Yen ^{c,*}

^a Fooyin Institute of Technology, Kaohsiung County, Taiwan, ROC

^b Department of Parasitology, National Cheng Kung University Medical College, Tainan, Taiwan, ROC

^c Department of Parasitology, Kaohsiung Medical College, No. 100, Shih-Chuan 1st Road, Kaohsiung, Taiwan, ROC

S.-M. Chye et al. / Acta Tropica 75 (2000) 9–17



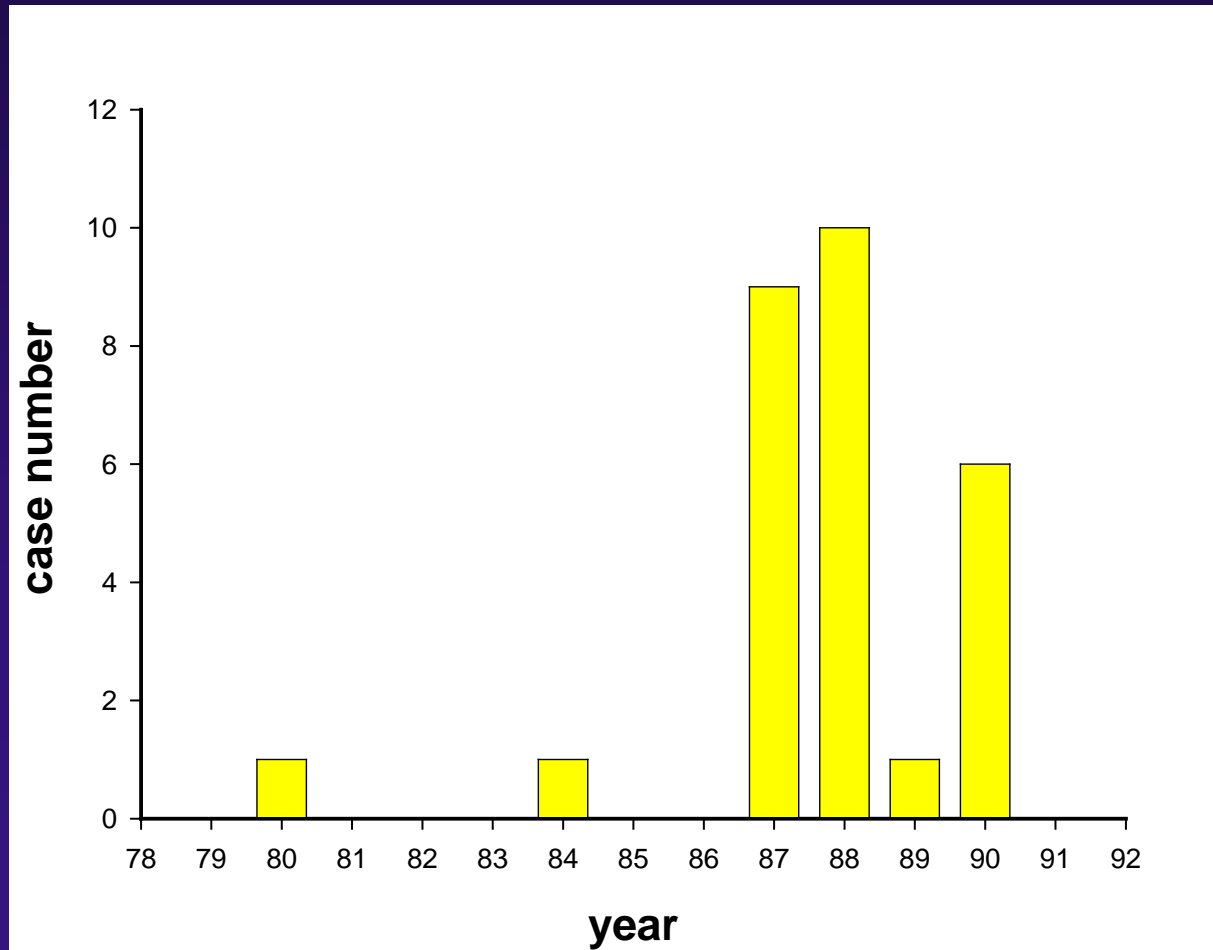
Acta Tropica
2000;75:9-17

**Diagnosis: Eosinophilic meningitis caused by
A. cantonensis infection**

Outline

- Case presentation of eosinophilic meningitis caused by *A. cantonensis* infection.
- Description of three outbreaks, clinical studies and epidemiological changes
- Intermediate host in Taiwan
- Control and prevention of *Pomacea canaliculata* in rice farm and water bamboo farm

Eosinophilic meningitis caused by *A.cantonensis* infection, VGH-KS, 1991-2001



Outbreak of eosinophilic meningitis
caused by *Angiostrongylus cantonensis* in
1998(87), 1999 (88) and 2001(90)

First outbreak in 1998

- Eight Thai laborers
- September 27-October 6, 1998
- *Pomacea canaliculata*
- Incubation period: 5-12 days
- One had bilateral abducens nerve palsy
- Four patients had negative MRI findings
- Treatment: steroid and mebendazole
- Outcome: good, no neurological complications

Tsai TH et al. J Microbiol Immunol Infect 2001;34:50-56

Second outbreak in 1999

- Nine Thai laborers
- October 31-November 25, 1999
- *Pomacea canaliculata* mixed with lemon juice and red pepper
- One had facial palsy
- MRI: varying degrees of meningeal enhancement and abnormal globus pallidus enhancement.
- Treatment: supportive treatment
- Outcome: good

Tsai et al. Am J Med 2001;111:109-114

Tsai et al. Am J Trop Med Hyg 2003;68:281-5

Third outbreak in 2001

- Five Taiwanese in a family (breakfast vendors)
- August 6, 2001
- Incubation time: medium 54 days
- Mixed Clover, leaf of sweet potatoes and apple for juice (精力湯)
- One had facial palsy
- Meningeal enhancement and high signal intensity at the subcortical white matter on T2WI and FLAIR image were observed in 4 patients.
- Treatment: Prednisolone 60 mg/day for 2 w
- Outcome: good

Tsai et al. Am J Trop Med Hyg 2004;71-222-6

Eosinophilic Meningitis Caused by *Angiostrongylus Cantonensis*: Report of 17 Cases

Hung-Chin Tsai, Yung-Ching Liu, Calvin M. Kunin, Susan Shin-Jung Lee, Yao-Shen Chen, Hsi-Hsun Lin, Tsung-Hung Tsai, Wei-Ru Lin, Chun-Kai Huang, Muh-Yong Yen, Chuan-Min Yen

PURPOSE: To describe two outbreaks of *Angiostrongylus cantonensis* infection that occurred in Kaohsiung, Taiwan, during 1998 and 1999, and to characterize the source of the outbreaks and the clinical manifestations of the disease.

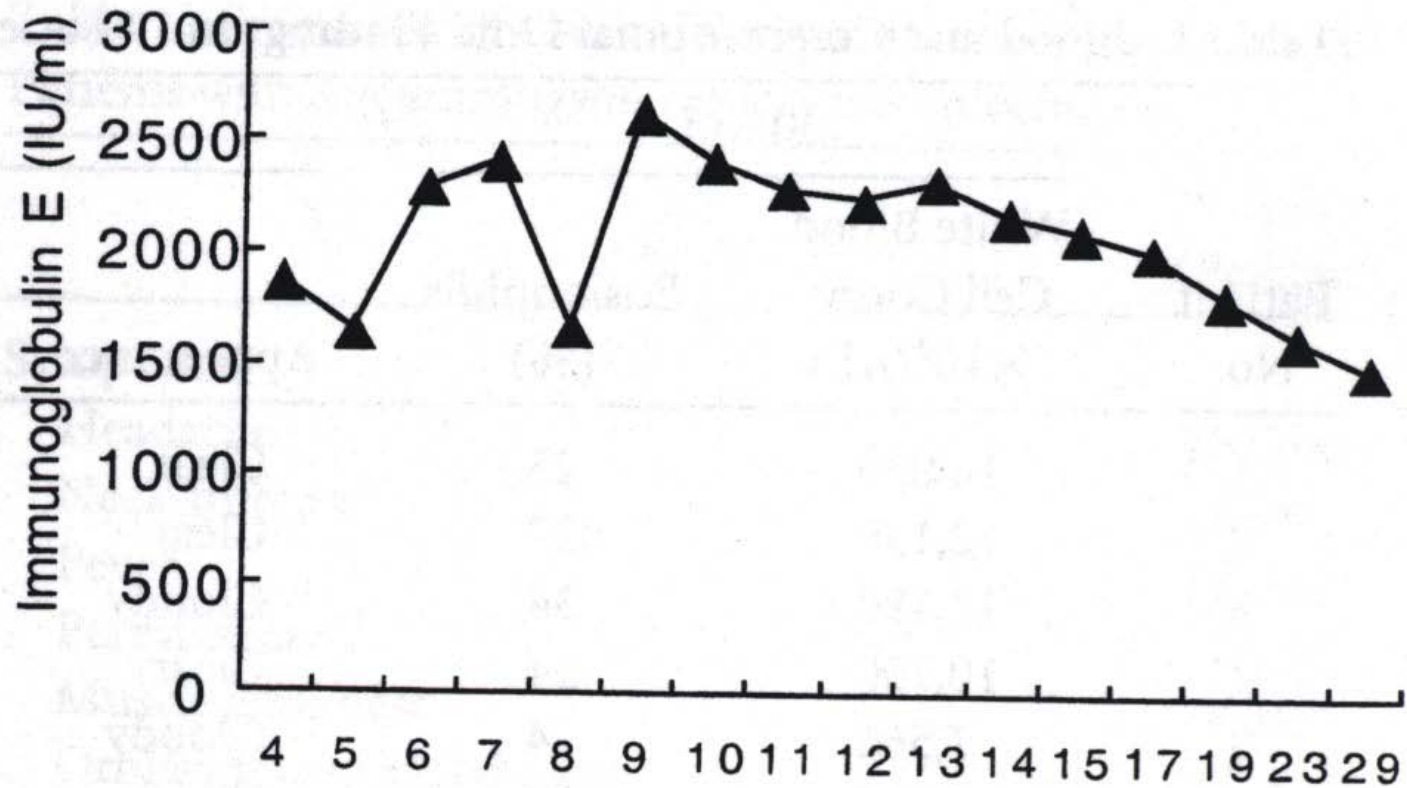
SUBJECTS AND METHODS: We performed a retrospective cohort study among Thai laborers with eosinophilic meningitis who ate raw snails (*Ampullarium canaliculatus*), as well as an environmental surveillance of larvae in snails.

RESULTS: We enrolled 17 Thai laborers in whom severe headache and eosinophilia developed within 4 to 23 days after eating raw snails. Twelve (71%) developed eosinophilic meningitis. Third-stage larvae were found in the cerebrospinal fluids of 2 patients and in all 12 tested snails. Specific antibodies to *A. cantonensis* were detected in serum from 16 of the patients and in cerebrospinal fluid from 5 of the patients. Central nervous system manifestations included headache (n = 17 [100%]), fever (n = 11 [65%]), Brudzinski's sign/stiff neck (n = 11 [65%]), hyperesthesia (n = 3 [18%]), cranial nerve palsy (n = 2 [12%]), diplopia (n = 2 [12%]), and ataxia (n = 1 [6%]). Laboratory findings included peripheral eosinophilia (n = 15 [88%]) and

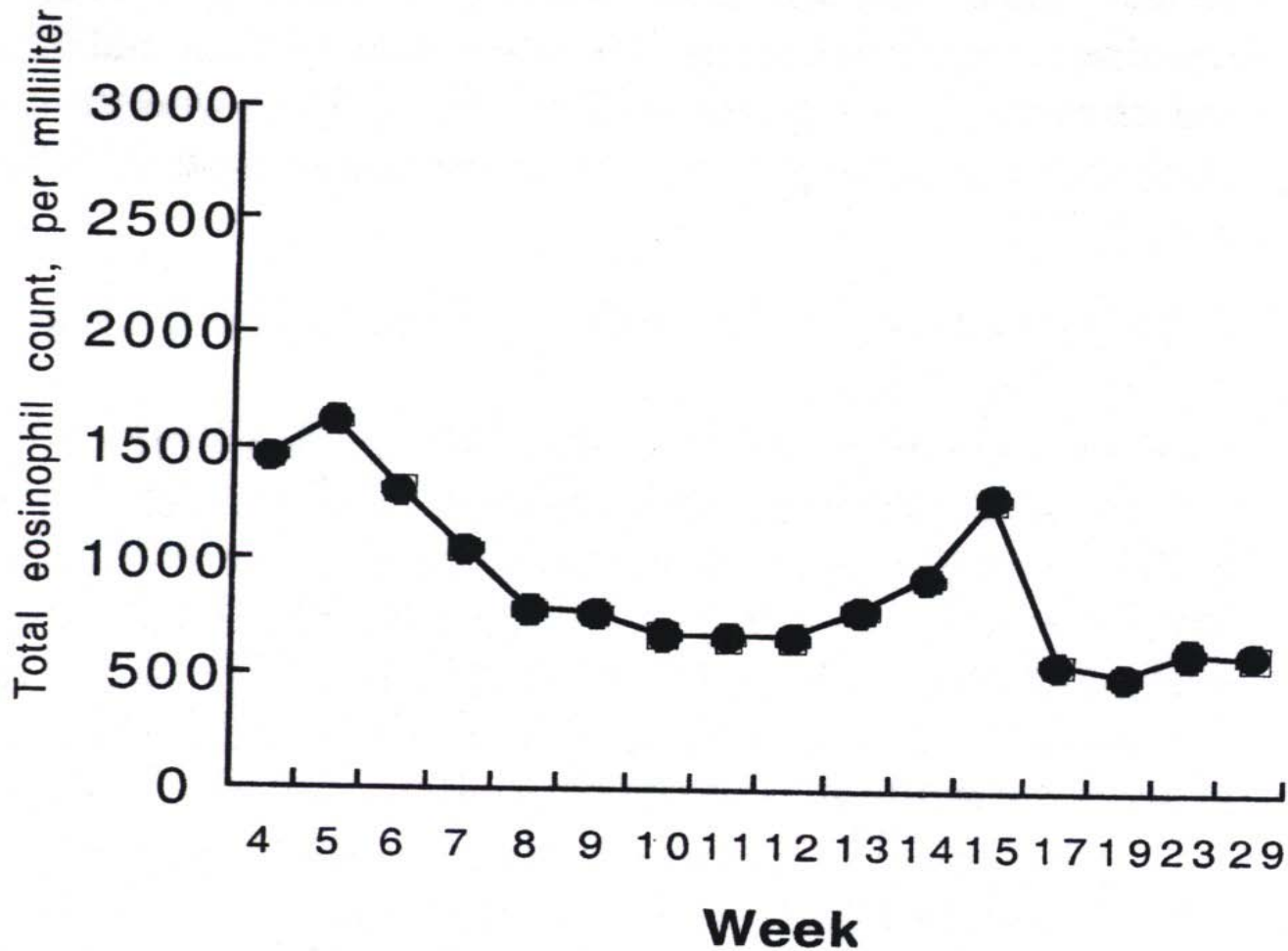
cerebrospinal fluid eosinophilia (n = 12 [71%]); elevated immunoglobulin (Ig) E levels (n = 13 [100%]); and transient increases in white blood cell count (n = 7 [41%]) and in serum levels of creatine kinase (n = 7 [41%]), transaminase (n = 3 [18%]), and lactate dehydrogenase (n = 2 [12%]). The severity of illness and eosinophilia were correlated with the number of ingested snails. Meningeal and basal ganglion enhancement was noted on magnetic resonance imaging in several patients. Treatment with mebendazole combined with glucocorticosteroids appeared to shorten the course of the infection, but not the number of relapses. The eosinophil count fell to normal within 3 months, but IgE levels remained elevated for as long as 6 months. All patients recovered with minimal neurologic sequelae.

CONCLUSION: Eosinophilic meningitis caused by *A. cantonensis* should be considered in patients who have headache or central nervous system manifestations after eating raw snails. *Am J Med.* 2001;111:109-114. ©2001 by Excerpta Medica, Inc.

Am J Med. 2001 Aug;111(2):109-14



Am J Med 2001;111:109-114

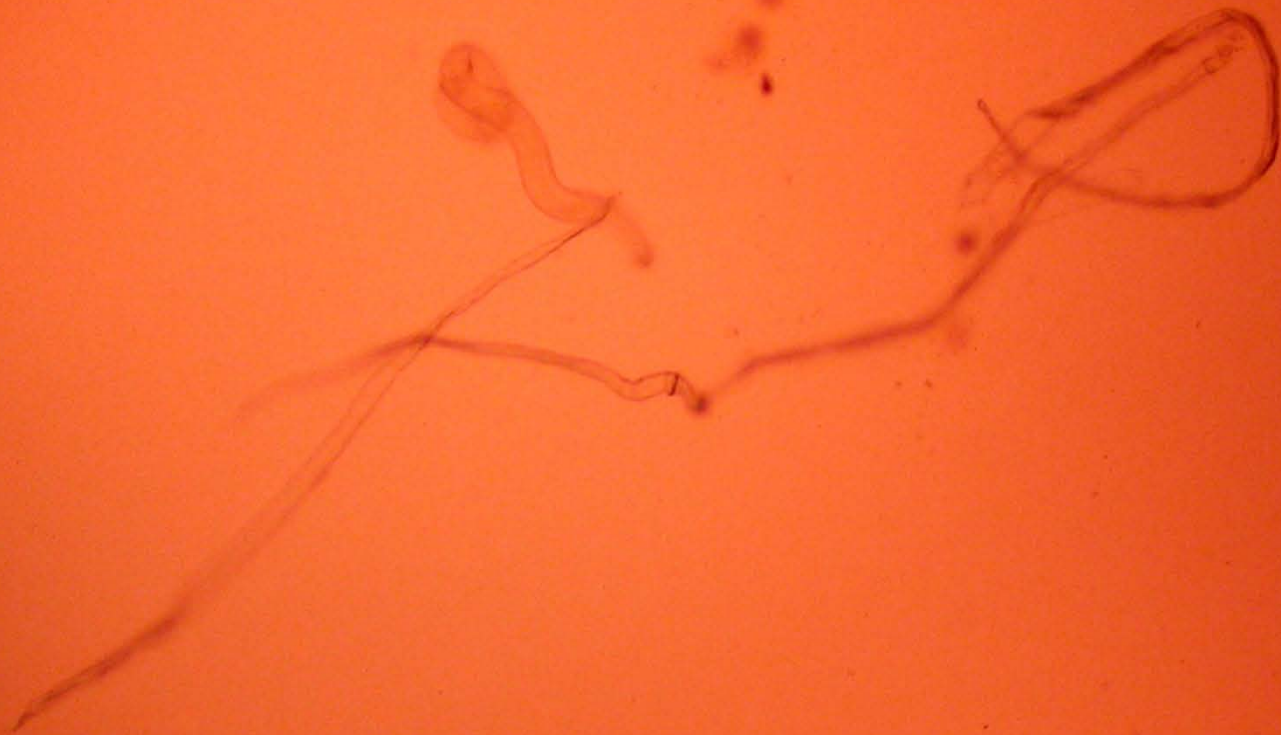

Am J Med 2001;111:109-114

Two glass test tubes are shown vertically against a dark background. The tube on the left contains a clear, colorless liquid. The tube on the right contains a pale yellow, turbid liquid. A white paper label is attached to the right tube, with some faint, illegible text. The tubes are resting on a green surface with a faint grid pattern.

Rice Water
CSF

Third stage larvae of *A. cantonensis*



EOSINOPHILIC MENINGITIS CAUSED BY *ANGIOSTRONGYLUS CANTONENSIS* ASSOCIATED WITH EATING RAW SNAILS: CORRELATION OF BRAIN MAGNETIC RESONANCE IMAGING SCANS WITH CLINICAL FINDINGS

HUNG-CHIN TSAI, YUNG-CHING LIU, CALVIN M. KUNIN, PING-HONG LAI, SUSAN SHIN-JUNG LEE,
YAO-SHEN CHEN, SHUE-REN WANN, WEI-RU LIN, CHUN-KAI HUANG, LUO-PING GER, HSI-HSUN LIN,
AND MUH-YONG YEN

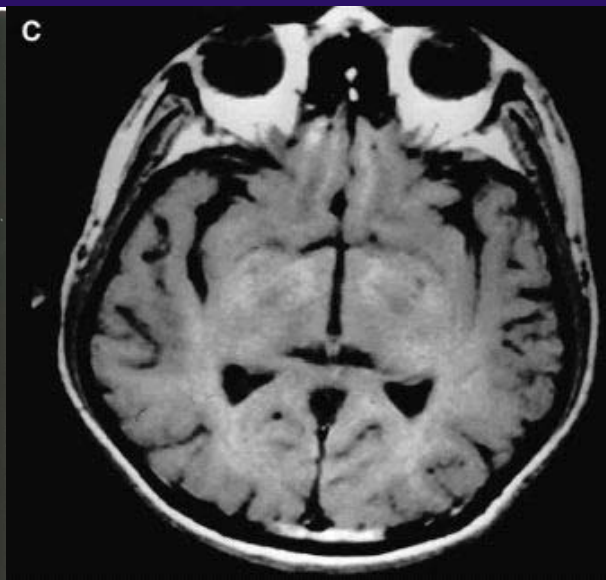
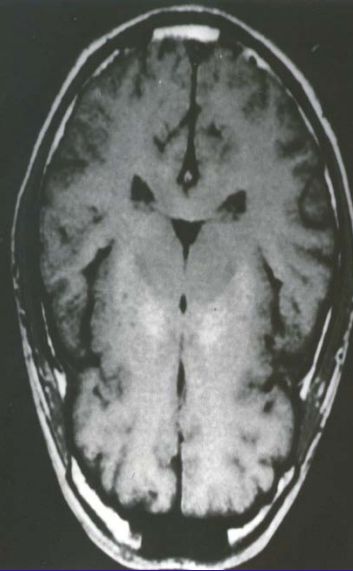
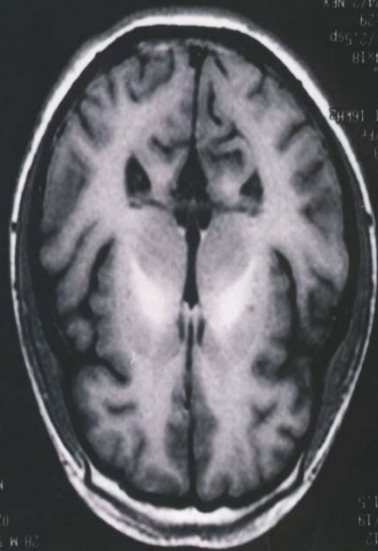
Section of Infectious Diseases, Department of Medicine, Kaohsiung Veterans General Hospital, Kaohsiung, Taiwan; National Yang-Ming University, Taipei, Taiwan, Republic of China; Department of Internal Medicine, Ohio State University, Columbus, Ohio; Department of Radiology, Kaohsiung Veterans General Hospital, Kaohsiung, Taiwan; Department of Medical Research, Kaohsiung General Veterans Hospital, Kaohsiung, Taiwan; Graduate Institute of Medicine, Kaohsiung Medical University, Kaohsiung, Taiwan

Abstract. *Angiostrongylus cantonensis* is the most common cause of eosinophilic meningitis worldwide. Human infection occurs after ingestion of the worms in raw snails or fish that serve as intermediate hosts. Two outbreaks of central nervous system infection with *A. cantonensis* occurred in Kaohsiung, Taiwan, during 1998 and 1999 among Thai laborers who ate raw snails. A detailed clinical studies of 17 of these patients was conducted, including study of 13 patients who underwent magnetic resonance imaging (MRI) scans of the brain. The MRI scans revealed high signal intensities over the globus pallidus and cerebral peduncle on T1-weighted imaging, leptomeningeal enhancement, ventriculomegaly, and punctate areas of abnormal enhancement within the cerebral and cerebellar hemisphere on gadolinium-enhancing T1 imaging, and a hyperintense signal on T2-weighted images. There was a significant correlation between severity of headache, cerebrospinal fluid (CSF) pleocytosis, and CSF and blood eosinophilia with MRI signal intensity in T1-weighted imaging ($P < 0.05$). Eosinophilic meningitis produced by *A. cantonensis* needs to added to the list of causes of hyperintense basal ganglia lesions found on T1-weighted MRI scans in tropical countries.

Am J Trop Med Hyg. 2003 Mar;68(3):281-5

There was a significant correlation between severity of headache, CSF eosinophilic pleocytosis with MRI signal intensity in T1-weighted imaging

Am J Trop Med Hgy 2003;68:281-5



Lesions with high signal intensity on spin-echo T1-weighted MR images

- *Lipids*
- *Calcification*
- *High protein content*
- *Laminar necrosis in cerebral infarction*
- *Neoplasms*
- *Paramagnetic substances such as methemoglobin, melanin, manganese and copper*

Cause of hyperintense basal ganglion

- *Intra-cranial Hemorrhage*
- *Hemorrhagic infarction*
- *Japanese Encephalitis*
- *Total Parenteral Nutrition*
- *Wilson's Disease*
- *Calcification*
- *Neurofibromatosis Type I*
- *Hypoxic-Ischemic Encephalopathy*
- *Acquired Non-Wilson's Hepatocerebral Degeneration*
- *Chorea-Ballism Associated with Hyperglycemia*

Lai PH et. AJR 1999;172:1109-1115

Clinical findings of 3rd outbreak

Blood/cerebrospinal fluid (CSF) findings and amount of health drink consisting of raw vegetable juice among five patients with *Angiostrongylus cantonensis* infection in southern Taiwan

Patient	Amount (mL) of drink and duration (months) of use	Blood			Cerebrospinal fluid			
		WBC ($\times 10^3/\mu\text{L}$)	Eosinophils (%)	WBC ($\times 10^3/\mu\text{L}$)	Protein (mg/dL)	Glucose (mg/dL)	Ratio (CSF/serum glucose)	Eosinophils (%)
1	360, 0.5	9,440	20	650	106	41	0.40	16
2	600, 2	8,750	21	525	130	44	0.42	73
3	360, 3	12,670	20	455	92	48	0.44	0
4	350, 3	6,020	14	830	91	44	0.44	45
5	360, 3	5,650	5	590	122	45	0.42	30

Tsai et al. Am J Trop Med Hyg 2004;71:222-226

OUTBREAK OF EOSINOPHILIC MENINGITIS ASSOCIATED WITH DRINKING RAW VEGETABLE JUICE IN SOUTHERN TAIWAN

HUNG-CHIN TSAI, SUSAN SHIN-JUNG LEE, CHUN-KAI HUANG, CHUAN-MIN YEN, ENG-RIN CHEN, AND YUNG-CHING LIU

Section of Infectious Diseases, Department of Medicine, Kaohsiung Veterans General Hospital, Kaohsiung, Taiwan, Republic of China; National Yang-Ming University, Taipei, Taiwan, Republic of China; Graduate Institute of Medicine, Kaohsiung Medical University, Kaohsiung, Taiwan, Republic of China

Abstract. The most common cause of eosinophilic meningitis is the rat lungworm *Angiostrongylus cantonensis*, a parasite that is endemic in the southeast Asian and Pacific regions. Outbreaks of eosinophilic meningitis associated with drinking raw vegetable juice are rarely reported, even in regions of endemic infection. We performed a cohort study among Taiwanese with eosinophilic meningitis who drank raw vegetable juice within three months of the onset of the outbreak. Clinical manifestations, laboratory examinations, and outcomes were prospectively followed. Five native Taiwanese met the case definition of eosinophilic meningitis. Specific antibodies to *A. cantonensis* were detected in the serum of five of the patients and in the cerebrospinal fluid (CSF) of four of the patients. Central nervous system manifestations included headache (n = 5 [100%]), Brudzinski's sign/stiff neck (n = 5 [100%]), hyperesthesia/paresthesias (n = 5 [100%]), and cranial nerve palsy (n = 1 [20%]). Laboratory findings included peripheral (n = 5 [100%]) and CSF eosinophilia (n = 4 [80%]), transient increases in the white blood cell count (n = 1 [20%]), and in serum levels of creatine kinase (n = 1 [20%]). Meningeal enhancement, as well as high signal intensity, at the subcortical white matter on T2 weighted and fluid attenuated inversion recovery images were observed on magnetic resonance imaging in four patients. There were three episodes of relapse during treatment and all resolved with after a lumbar puncture and/or administration of steroids. At the 12-month follow up, all five patients had recovered without neurologic sequelae. Risk factors identification showed that consumption of raw vegetable juice was associated with illness (Pearson correlation test $r = 0.867$, $P = 0.01$). There was association between the presence of raw vegetable juice and CSF eosinophilia (Spearman's correlation test $r = 0.816$, $P = 0.004$).

Tsai et al. Am J Trop Med Hyg 2004;71:222-226

Neurotropic factor in eosinophilic meningitis caused by *A. cantonensis*

- Dynamic changes of **hepatocyte growth factor** in **eosinophilic meningitis** caused by *Angiostrongylus cantonensis* infection -high concentrations of HGF in the CSF occur in **eosinophilic meningitis**, and may have a role in protecting against endothelial injury and reducing BBB dysfunction.

Tsai et al .Am J Trop Med Hyg 2009;80:980-2

- **Vascular endothelial growth factor** is associated with blood brain barrier dysfunction in **eosinophilic meningitis** caused by *Angiostrongylus cantonensis* infection

Tsai et al .Am J Trop Med Hyg 2007;76:592-5

- Association of **matrix metalloproteinase-9** and tissue inhibitors of **metalloproteinase-4** in cerebrospinal fluid with blood-brain barrier dysfunction in patients with **eosinophilic meningitis** caused by *Angiostrongylus cantonensis*

Tsai et al .Am J Trop Med Hyg 2008;78:20-7

TABLE 1

Pearson correlation test showed an association between VEGF_{CSF}, CSF protein, CSF white cell counts and CSF eosinophil counts

Variable	VEGF _{CSF1}		VEGF _{CSF2}		VEGF _{CSF3}	
	r	p	r	P	r	p
CSF protein1	0.334	0.465	0.788	0.035*	0.788	0.035*
CSF protein2	0.128	0.742	0.829	0.006*	0.641	0.063
CSF protein3	0.237	0.701	0.860	0.061	0.872	0.054
CSF wbc1	0.337	0.460	0.795	0.033*	0.795	0.033*
CSF wbc2	0.505	0.166	0.817	0.007*	0.932	< 0.001*
CSF wbc3	0.754	0.084	0.577	0.231	0.886	0.019*
CSF eosin	0.15	0.001*	0.806	0.009*	0.685	0.042*

VEGF_{CSF1}, VEGF_{CSF2}, VEGF_{CSF3}, represent the CSF VEGF level at presentation (n = 7), 1 week (n = 9), and 2 weeks later (n = 6). CSF protein 1, CSF protein 2, CSF protein 3 are the protein concentration in CSF at presentation, 1 week, and 2 weeks after admission. CSF wbc1, CSF wbc2, CSF wbc3 show the white cell count in CSF at presentation, 1 week, and 2 weeks later. CSF eosin represented CSF eosinophil counts at presentation.

* showed $P < 0.05$.

Am J Trop Med Hyg 2007 Mar;76(3):592-5

Association of Matrix Metalloproteinase-9 and Tissue Inhibitors of Metalloproteinase-4 in Cerebrospinal Fluid with Blood-Brain Barrier Dysfunction in Patients with Eosinophilic Meningitis Caused by *Angiostrongylus cantonensis*

Hung-Chin Tsai, Li-Yu Chung, Eng-Rin Chen, Yung-Ching Liu, Susan Shin-Jung Lee, Yao-Shen Chen, Cheng-Len Sy, Shue-Ren Wann, and Chuan-Min Yen*

Section of Infectious Diseases, Department of Medicine, Kaohsiung Veterans General Hospital 386, Kaohsiung City, Taiwan, Republic of China; National Yang-Ming University, Taipei, Taiwan, Republic of China; Department of Parasitology and Graduate Institute of Medicine, Kaohsiung Medical University, Kaohsiung, Taiwan, Republic of China

TABLE 1

Mean \pm SD (ranges) Q_{Alb} values and concentrations of MMPs and TIMPs in CSF of patients with eosinophilic meningitis caused by *Angiostrongylus cantonensis* infection*

Subject	Q_{Alb}	MMP-2 (ng/mL) [†]	MMP-9 (ng/mL)	TIMP-1 (ng/mL)	TIMP-2 (ng/mL)	TIMP-4 (pg/mL)
Patient (n = 40)	4.27 \pm 2.06 (1.56–9.23) [‡]	33.35 \pm 12.79 (13.80–55.50) [§]	9.63 \pm 4.59 (1.80–17.80) [‡]	385.9 \pm 197.57 (147.00–940.00) [‡]	38.45 \pm 11.28 (12.00–69.00)	392.65 \pm 158.04 (185.20–899.30)
Control (n = 28)	1.25 \pm 0.20 (0.96–1.88)	30.28 \pm 39.03 (15.80–181.00)	1.85 \pm 0.92 (1.00–4.90)	59.18 \pm 21.52 (11.00–95.00)	35.04 \pm 7.65 (21.00–56.00)	1,311.94 \pm 760.39 (453.10–3,201.00)

* Q_{Alb} = cerebrospinal fluid (CSF):serum albumin ratio $\times 10^3$; MMPs = matrix metalloproteinases; TIMPs = tissue inhibitors of metalloproteinase.

[†] MMP-2 was only measured in 23 patients and 17 controls, respectively.

[‡] $P < 0.001$ by Mann-Whitney U test.

[§] $P < 0.05$, by Mann-Whitney U test.

□ CASE REPORT □

Encephalitis Caused by *Angiostrongylus cantonensis* after Eating Raw Frogs Mixed with Wine as a Health Supplement

Hung-Chin Tsai^{1,2}, Ping-Hong Lai^{2,3}, Cheng-Len Sy¹, Susan Shin-Jung Lee^{1,2},
Chuan-Min Yen⁴, Shue-Ren Wann^{1,2} and Yao-Shen Chen^{1,2}

Abstract

Angiostrongylus cantonensis also known as the rat lungworm, is prevalent in the Pacific Islands and south-east Asia and is the most common cause of eosinophilic meningitis in humans. Although frogs and toads are known as paratenic hosts of *A. cantonensis*, they are rarely reported as the infectious source of human angiostrongyliasis. We report a case of encephalitis caused by *Angiostrongylus cantonensis* after eating raw frogs mixed with wine as a health supplement. Prednisolone at a dose of 1 mg/kg/day was prescribed for 14 days successfully. We advise that travelers and residents of endemic areas should avoid eating raw frogs and a public caution on the danger of eating raw wild animal products or the whole animal is recommended to alleviate such accidental infection.

Key words: *Angiostrongylus cantonensis*, eosinophilic meningitis, encephalitis

(Intern Med 50: 771-774, 2011)

(DOI: 10.2169/internalmedicine.50.4193)

Table 3 Clinical characteristics in four series of patients with eosinophilic meningitis caused by *Angiostrongylus cantonensis*

Characteristics	Taiwan			Thailand
	Yii ^a , ⁴	Hwang ¹⁸	Present study	Punyagupta et al. ¹⁹
Number of patients	125	87	37	484
Study period (A.D.)	1968–1969	1976–1991	1991–2009	1965–1968
Age group				
0–9-yr-old, <i>n</i> (%)	88 (70)	70 (80)	2 (5)	18 (4)
10–19-yr-old, <i>n</i> (%)	18 (14)	17 (20)	0 (0)	73 (15)
>20-year-old, <i>n</i> (%)	14 (11)	0 (0)	35 (95)	393 (81)
Unknown	5 (4)	0 (0)	0 (0)	0(0)
Death, <i>n</i> (%)	4 (3)	4 (5)	2 (5)	1 (<1)
Incubation period (days, mean) (range)	NR	13.0(2–45)	22.6 (3–80)	17 (2–34)
Clinical manifestations, <i>n</i> (%)				
Headache	98 (86)	51 (59)	29 (78)	477 (98)
Fever	91 (80)	80 (92)	25 (68)	177 (37)
Neck stiffness	45 (40)	69 (79)	17 (46)	312 (64)
Muscle weakness	19 (17)	19 (22)	15 (41)	4 (1)
Brudzinski's sign/Kernig's sign	50 (44)	41 (47)	12 (32)	27 (6)
Hyperesthesia/paresthesia	32 (28)	4 (5)	11 (30)	181 (37)
Facial palsy	1 (1)	9 (10)	1 (3)	20 (4)
Paralysis of the extraocular muscles	9 (8)	5 (6)	4 (11)	16 (3)
Laboratory data ^b				
Range of white blood cell ($\times 10^3/\mu\text{L}$)	5.75–35.25	NR	4.5–25.42	NR
Patients with WBC $> 10.0 \times 10^3/\mu\text{L}$ ^b	NR	73 (84%)	17 (50%)	NR (56%)
Percentage of patients with peripheral-blood eosinophilia	100	85	68	73
Range of CSF white blood cell ($/\mu\text{L}$)	46–4,354	NR	0–1,660	500–2,000
Percentage of patients with CSF eosinophilia (criterion)	98 (>10%)	91 (>10%)	54 ($\geq 10\%$)	96 (>10%)
Percentage of patients with elevated CSF protein (criterion)	NR	61 (>45 mg/dL)	89 (>45 mg/dL)	68 (>50 mg/dL)

^a Further clinical manifestation were collected in 114 patients.

^b Number (percent).

CSF = cerebrospinal fluid; NR = not reported.

Outline

- Case presentation of eosinophilic meningitis caused by *A. cantonensis* infection.
- Description of three outbreaks, clinical studies and epidemiological changes
- **Intermediate host in Taiwan**
- Control and prevention of *Pomacea canaliculata* in rice farm and water bamboo farm

Intermediate host

- The major intermediate hosts in Taiwan are the African giant snail (*Achutina fulica*) and the golden apple snail (*Pomacea canaliculata*). *Pomacea canaliculata* was introduced to Taiwan in 1979 as a food source. It spread widely in paddy fields and drainage ditches and has become an important cause of outbreaks of eosinophilic meningitis.

Tsai et al Am J Med 2001;111:109-114

- Field studies in southern Taiwan revealed that 15% to 28% of *Pomacea canaliculata* contain third-stage larvae of *A. cantonensis*

Yen et al J Trop Med Hyg 1990;93:347-50

Outline

- Case presentation of eosinophilic meningitis caused by *A. cantonensis* infection.
- Description of three outbreaks, clinical studies and epidemiological changes
- Intermediate host in Taiwan
- Control and prevention of *Pomacea canaliculata* in rice farm and water bamboo farm



中文名：青魚

英文名：Snail carp, Chinese roach, Black carp

學名：Mylopharyngodon piceus Richardson 俗

名：烏溜、鰻仔、黑鯪

Extract Astaxanthin (natural anti-oxidant) from egg of *Pomacea canaliculata*

- Local Bio-pharmapseutic company in Taiwan encourage farmers to raise *Pomacea canaliculata* as a source of *Astaxanthin*
- Bureau of Animal and Plant Health Inspection and Quarantine ,Council of Agriculture, Executive Yuan
- Strengthen the monitoring, warning and notification systems for plant diseases (*Pomacea canaliculata*)
- Penalty of 1000 to 5000 USD to those farmers to raise *Pomacea canaliculata*

Summary

- Most cases of *A. cantonensis* eosinophilic meningitis in Taiwan have been reported in children exposed to the African giant snail (*A. fulica*). There is usually a history of eating or playing with snails or slugs.
- More recently there have been several outbreaks among adults, particularly Thai laborers who have eaten golden apple snails (*A. canaliculatus*).
- Serum epidemiology data in our community is not available, but we believe it is very low.
- Government has strengthen the monitoring, and control systems for *Pomacea canaliculata* in farm